



## Review

## PET-imaging of brain plasticity after cochlear implantation

K. Strelnikov<sup>a, b, 1</sup>, M. Marx<sup>c, 1</sup>, S. Lagleyre<sup>c</sup>, B. Fraysse<sup>c</sup>, O. Deguine<sup>a, b, c</sup>, P. Barone<sup>a, b, \*</sup><sup>a</sup> Université de Toulouse, Cerveau & Cognition, Université Paul Sabatier, Toulouse France<sup>b</sup> CerCo, CNRS UMR 5549, Toulouse France<sup>c</sup> Service d'Oto–Rhino–Laryngologie, Hôpital Purpan, Toulouse, France

## ARTICLE INFO

## Article history:

Received 4 June 2014

Received in revised form

5 September 2014

Accepted 1 October 2014

Available online 16 October 2014

## ABSTRACT

In this article, we review the PET neuroimaging literature, which indicates peculiarities of brain networks involved in speech restoration after cochlear implantation. We consider data on implanted patients during stimulation as well as during resting state, which indicates basic long-term reorganisation of brain functional architecture. On the basis of our analysis of neuroimaging literature and considering our own studies, we indicate that auditory recovery in deaf patients after cochlear implantation partly relies on visual cues. The brain develops mechanisms of audio-visual integration as a strategy to achieve high levels of speech recognition. It turns out that this neuroimaging evidence is in line with behavioural findings of better audiovisual integration in these patients. Thus, strong visually and audio-visually based rehabilitation during the first months after cochlear implantation would significantly improve and fasten the functional recovery of speech intelligibility and other auditory functions in these patients. We provide perspectives for further neuroimaging studies in cochlear implanted patients, which would help understand brain organisation to restore auditory cognitive processing in the implanted patients and would potentially suggest novel approaches for their rehabilitation.

*This article is part of a Special Issue entitled <Lasker Award>.*

© 2014 Elsevier B.V. All rights reserved.

## 1. Role of brain plasticity after cochlear implantation

The evolution of cochlear implants (CI) during the last 30 years has led to a considerable success in the functional rehabilitation of deaf (Blamey et al., 2013; Moller, 2006); modern cochlear implants allow deaf patients to understand spoken speech and in some cases even to listen to music. As CI technology is improving and safer surgical techniques are being implemented, indications for cochlear implantation are being extended (Deggouj et al., 2007). The standard indication remains postlingually deaf adult but more and more attention is being paid to the benefit of cochlear implantation in young children of 1–2 years or even less, in adults with residual hearing and even in prelingually deaf adults.

Permanent growth in the number of cochlear implantations all over the world posits the problem of the physiological explanation of the neural mechanisms underlying the impressive

improvements in hearing after cochlear implantation. It is known that during the first months after implantation hearing remains poor, perceived sounds remain largely indecipherable (Tyler et al., 1997). Only with time, in several months after implantation, patients reach a satisfactory level of understanding speech and discrimination environmental sounds. Keeping in mind that sensory input provided by the implant remains unchanged, it is clear that mechanisms of brain reorganization after cochlear implantation play a major role in auditory improvement.

Of importance, the comparatively short-term adaptive plasticity corresponding to the re-activation of the auditory system by the implant occurs on the basis of a preceding long-term adaptive plasticity induced by the long period of hearing loss. Given the strong importance of visual cues in normal speech processing as well as during hearing loss (Bernstein et al., 2000, 2001; Rouger et al., 2007; Strelnikov et al., 2009), the adaptive cross-modal plasticity implicating visual and visuo-auditory brain areas will become of crucial importance in speech comprehension recovery. Thus, studies of brain plasticity after cochlear implantation may help clarify an important mechanism of functional rehabilitation. The CerCo laboratory and the ENT department of the Toulouse hospital have developed a long-term

\* Corresponding author. Cerveau & Cognition, CNRS UMR 5549, Pavillon Baudot, CHU Purpan, BP 25202, 31052 Toulouse Cedex, France.

E-mail address: [barone@cerco.ups-tlse.fr](mailto:barone@cerco.ups-tlse.fr) (P. Barone).

<sup>1</sup> The authors contributed equally to the manuscript.

collaboration to assess the role of brain plasticity for the recovery of auditory function with an emphasis on neuronal mechanism supporting a specific visuo-auditory synergy (Barone and Deguine, 2011). The present review will summarize this work in light of other studies that have explored how the deafened brain adapts to electrically-induced auditory stimulation. Along with their fundamental value, these studies may guide the elaboration of novel and more efficient approaches for functional training of the implanted patients.

## 2. Peculiarities of the neuroimaging approach

Functional neuroimaging in human refers to a class of non-invasive techniques that aim to measure various correlates of neural activity: PET (positron emission tomography), fMRI (functional magnetic resonance imaging), EEG (electroencephalography) and MEG (magnetoencephalography). According to the measured correlates of neural activity, these techniques can be divided into the following groups: metabolic (PET with labelled glucose etc.), haemodynamic (PET with labelled water, fMRI, fNIRS) and electrophysiological (EEG, MEG). Either of them can provide information for the neural activity during a resting condition and with a certain cognitive load.

Due to the artefacts caused by the implant, EEG recordings are highly contaminated and should be interpreted with caution (Debener et al., 2008). The internal implant contains a magnet, which holds the external sound processor coil in place. When placed in the gradient field of MRI scanner, this magnet can cause a huge artefact in the resulting image (Crane et al., 2010). Besides, in cochlear implants, the signal is transmitted from the external microphone to the implanted receiver through radio-frequency waves, a configuration that can be distorted by the gradient field and cause deleterious interactions with radio-frequency excitation pulses in MRI. In consequence, though some of today cochlear implants being switched off are MRI compatible for clinical purposes, it prevents the implant from being used with auditory stimulation and such studies are realised with PET scan. PET scan allows the usage of fully functional implants like in everyday life, which activate auditory pathways in the most physiological way including the free field sound perception. Even if fMRI-compatible implants were available, the problem of the very intense noise in fMRI would remain, while in PET the noise of the camera is quite low so that in most cases the interference of noise with stimulation during PET studies is negligible. On the other hand, functional near-infrared spectroscopy (fNIRS) represents a recent non-invasive neuroimaging method as, similarly to fMRI, it relies on changes in blood haemoglobin concentrations that can be associated with neural activity. Such a method, which is safe to use repeatedly and which has no interference with cochlear implant devices, may represent a novel perspective for the studies of the brain after cochlear implantation (Pollonini et al., 2014; Sevy et al., 2010) especially in children.

According to statistical recommendations for neuroimaging, the full-brain analysis requires a correction for multiple dependent comparisons (Friston, 2003). However, this correction under some circumstances may lead to the absence of significant activations (e.g., small number of subjects, great variability of neural responses, some peculiarities of the experimental paradigm like passive listening or too subtle cognitive contrasts). In this case, results presented at non-corrected level of significance may be also of a certain interest but they should be considered with some caution depending on neuropsychological plausibility and should be referred to as tendencies. Further discussion concerning the balance between specificity and sensitivity in neuroimaging studies can be obtained in recent study (Bennett et al., 2009).

## 3. Studies of the resting state

The resting state activity of the brain is also referred to as default-mode activity (Mazoyer et al., 2001; Raichle and Snyder, 2007). It is known that the task-related energy changes of the brain are relatively small compared to the basal level of energy turnover at rest (Fiser et al., 2004; Giove et al., 2003; Kenet et al., 2003). High brain activity at rest may serve to monitor the current status of the individual relative to the environment (Raichle and Mintun, 2006; Raichle and Snyder, 2007). By predicting the common possible states of the environment, the brain is able to track any deviance of the real incoming information from the predicted patterns (Strelnikov, 2007). In this view, resting activity might represent the intrinsic functional organization of the brain with internal representations and behavioural patterns (Gusnard and Raichle, 2001; Raichle and Snyder, 2007), which is important for adaptation to the permanent and predictable conditions of the environment.

Pioneer studies on brain activity at rest have revealed abnormal metabolic levels in the deprived primary sensory areas (Deggouj et al., 1995; Veraart et al., 1990; Wanet-Defalque et al., 1988) reflecting the appropriation by the remaining sensory modalities (Lee et al., 2001, 2007b). Similarly, resting-state activity in CI patients at rest reflects the long-term plasticity of the brain after deafness and cochlear implantation. In early studies at rest, Ito et al. (Ito et al., 1993) demonstrated reduced glucose metabolism in the auditory cortex after the long-term deafness, which was restored to near-normal levels in experienced patients with CI.

In children, the glucose metabolism increased after CI (relative to that before CI) in several brain regions including the bilateral ventral posteromedial thalamic regions, the left cuneus, the right lingual gyrus (interpreted as parts of the visual network) and the posterior cingulate gyrus, which is the directed attention centre (Conte et al., 2008). Compared to normal hearing adults, extensive hypermetabolic regions were also found in the visual network: in the occipito-parietal regions bilaterally and in the posterior medial part of the left lingual gyrus. On the contrary, hypometabolic regions included bilaterally the thalamus, brain stem, cingulate gyrus and inferior prefrontal regions possibly involved in linguistic functions (Kang et al., 2004). It is noteworthy that the activity level of brain areas assessed before implantation could be a reliable prognosis of the level of auditory recovery after cochlear implantation. Indeed, children who respond best to cochlear implantation are those with the highest resting-state metabolism in the linguistic network (Broca area, the left dorso-lateral prefrontal cortex and the left angular gyrus), prior to implantation (Giraud and Lee, 2007). Interestingly, the level of activity observed in the deprived primary auditory cortex does not allow estimating the outcomes of the implantation. On the opposite, the key areas necessary for the good auditory recovery are located outside the low levels auditory areas and concern mainly the prefrontal regions but also of the occipital visual areas. However, it remained unclear whether this was related to deafness plasticity, which should be present shortly after the implantation.

In our study performed in post-lingual deaf patients, we questioned how resting state can be modulated by the progressive experience with the implant (Strelnikov et al., 2010). We presented evidence that at rest, compared to normal hearing subjects, cochlear implanted deaf patients show specific regions of lower or higher activity. These brain regions correspond to the known reorganized network involved in speech comprehension after cochlear implantation (Giraud et al., 2000; Green et al., 2008). Shortly after implantation, CI subjects showed a relative increase of cerebral blood flow in the visual cortex and in the posterior temporal areas, which are related to speech analysis. A relative signal

decrease was observed in the superior temporal auditory cortex and Broca area. Importantly, there was an increment of activity in these areas from the time of activation of the implant to about a year after implantation. All of these areas are involved in several aspects of speech processing including speech perceived through the visual channel. Thus, we might suggest that their reorganization at rest reflects the adaptive pre-wiring of the brain needed for optimal speech perception after implantation. The increase of activity in the superior temporal auditory cortex and Broca area are related to the restored auditory perception through the implant. An increase of activity in the visual cortex and in the posterior temporal area, known as the center of audiovisual integration, indicates an increase of the usage of long-term audiovisual strategies in experienced CI patients. As this activity depends upon experience with cochlear implants, we propose that it reflects cortical plasticity induced by the strategy for speech comprehension. This plasticity is developed progressively by the patients who combine visual and auditory speech cues.

#### 4. Unilateral implantation and hemispheric asymmetry

In post-lingually deaf adult CI users, high progress of speech recovery is observed during the first year after cochlear implantation, but there is a large range of variability in the CI outcomes and the temporal evolution of recovery (Lazard et al., 2012; Rouger et al., 2007; UKCISG, 2004). Further, some aspects of speech perception remain difficult including speech understanding in noise, voice identification, and prosody recognition; these difficulties can be related to the limitations of current cochlear implants (Gfeller et al., 2002; Peng et al., 2009). However some auditory deficits are probably due to the fact that in a majority of cases only a unilateral implantation is performed in bilaterally deaf patients (Aggarwal and Green, 2012). In consequence, the rehabilitated patients could be considered as unilateral deaf patients. Indeed, these patients present most of the deficiencies associated to the unilateral deafness such as poor localization of sounds in space or high vulnerability of speech understanding in noisy situations. Further, it has been proposed that the side of the implanted ear can impact the post-lingual deafness-induced reorganization because of the specialization of the left hemispheric capacities in language processing (Lazard et al., 2012). Indeed, there are evidences that cortical plasticity affects differently the right and left hemispheres after unilateral deafness (Hanss et al., 2009); such phenomena also concern visual reorganization induced by profound deafness (Sandmann et al., 2012).

Early studies have addressed the question of response asymmetry in the auditory cortex after unilateral implantation (Naito et al., 1995). During stimulation with noise, mean regional cerebral blood flow (rCBF) increase was significantly greater in the primary auditory area on the side contralateral to the implant than on the ipsilateral side. However, no contralateral lateralization was observed for speech stimulation thus far. On the other hand, in the study of Wong et al. (Wong et al., 1999) the implanted in the right ear subjects showed more extended foci of activations in the right superior and middle temporal regions though not compared directly with controls. This was demonstrated in word-silence and sentence-silence contrasts. In the implanted to the right ear patients during word perception shortly after implantation, Ito et al. (Ito et al., 2004) observed a tendency for higher activation in the posterior middle temporal region bilaterally, but also lower activation in the auditory cortex bilaterally as compared to controls ( $p < 0.001$ , uncorrected).

As no convincing effects were found for the laterality of implantation, most of the studies were done in a mixed group of patients with unilateral cochlear implants (uCI). These studies

using different speech stimulation demonstrated that though there is deactivation in the auditory cortex compared with controls, the surrounding associative temporal cortex can elicit compensatory over-activation. The compensatory nature of these over-activations is clear because in well performing uCI users, activations were significantly stronger than in poorly performing ones in the associative auditory cortex but not in the primary auditory cortex (Fujiki et al., 2000; Green et al., 2005, 2008). During sentence processing in a Naito et al. (2000) observed a tendency for higher activation as compared with normal controls bilaterally in the associative temporal cortices. Surprisingly enough, they also reported a tendency for over-activation in Broca area and its right hemisphere homologue ( $p < 0.01$ , uncorrected for multiple comparison). As could be expected, postlingually implanted subjects showed more activation in the Wernicke area than prelingually implanted ones (Okazawa et al., 1996).

Bilaterally implanted patients demonstrate better performance in recognition of words and phrases both in quiet and in noise (Dunn et al., 2008; Ricketts et al., 2006). Besides, comprehension scores are higher in the bilateral listening condition compared with the scores for the better ear alone (Mosnier et al., 2009; Tyler et al., 2007). Bilaterally implanted subjects are also better than unilateral implant users in sound-direction identification (Neuman et al., 2007). Based on these behavioural differences between uni- and bilateral implantations, we analysed whether brain activity after bilateral implantation is closer to normal or represents a specific compensatory network. Comparing the effects of bilateral and unilateral stimulation in patients with bilateral implants (Strelnikov et al., 2011), we observed no over-activation in patients for binaural stimulation, with a hypo-activation in the right temporal cortex. Thus, binaural stimulation through cochlear implants can be considered at the neurofunctional level as advantageous compared to the monaural because the pattern of brain activity is closer to normal-hearing controls. A similar conclusion of a benefit in bilateral cochlear implantation has been made in patients when discriminating human voice (Coez et al., 2013). However, in bilaterally implanted patients, in situations of monaural stimulation, and compared with monaurally stimulated controls, patients demonstrated more activation contralaterally to the stimulation side in the posterior temporal cortex and in the cerebellum. Such differences have been interpreted as reflecting higher cognitive or attentional load in this specific and “unnatural” condition for the patients (Strelnikov et al., 2011). In consequence, when comparing to NHS, the patterns of brain activity are different in uni- and bilaterally implanted patients. Indeed, brain reorganisation after bilateral cochlear implantation is rather global involving complex relations in a distributed neural network across the cortex. Some authors suggested that the differences between unilateral CI patients in speech processing are partly related to the compensation mechanisms for monaurality in patients (Aggarwal and Green, 2012) in addition to different strategies developed by the patients to process speech involving more phonological processing (Giraud et al., 2001a; Ito et al., 2004).

#### 5. Brain plasticity and audiovisual integration of speech

The nature of speech is multisensory. Indeed, visual information can improve speech intelligibility, especially when presented simultaneously with a noisy or degraded acoustic signal (Benoit et al., 1994; Grant and Braida, 1991; MacLeod and Summerfield, 1987; Ross et al., 2007; Sumbly and Pollack, 1954; Summerfield, 1979). Moreover, visual information is also useful for speech detection and intelligibility even when acoustic information is perfectly clear (Arnold and Hill, 2001; Campbell, 2008; Reisberg et al., 1987). Thus, the role of audiovisual interaction in speech

processing is crucial to understand functional plasticity during deafness and recovery.

During the partial restoration of audition by cochlear implants, visual counterpart of speech helps decipher auditory information and finally increases the capacities for auditory discrimination (Barone and Deguine, 2011). Such visuo-auditory synergy is also observed at the neuro-functional level in CI users, in which, after implantation, there is a progressive increase of activation in the visual areas induced by auditory stimulations (Giraud et al., 2001b). Further, a positive correlation between activations of the associative auditory and visual cortices was found both for noises and meaningful (speech and environmental) sounds. However, the correlation was significantly greater for the meaningful sounds compared to that observed for noises, which might suggest a link with mental imaging. The authors also found a positive correlation of the lip-reading scores with the activation of the visual cortex (right cuneus). Thus, visual activity of the brain is involved in speech processing after implantation.

Importantly, audiovisual brain plasticity occurs already in deaf patients before implantation. During deafness, visual speech processing induces a colonisation of auditory areas by visual functions: activations in auditory areas have also been found during speech-reading (Lee et al., 2007a; MacSweeney et al., 2002) and in sign language perception (Nishimura et al., 1999; Petitto et al., 2000). This colonization may be a neural underpinning of the capacity of deaf people to have higher speech-reading performance than normally hearing subjects (Bernstein et al., 2000, 2001; Rouger et al., 2007; Strelnikov et al., 2009).

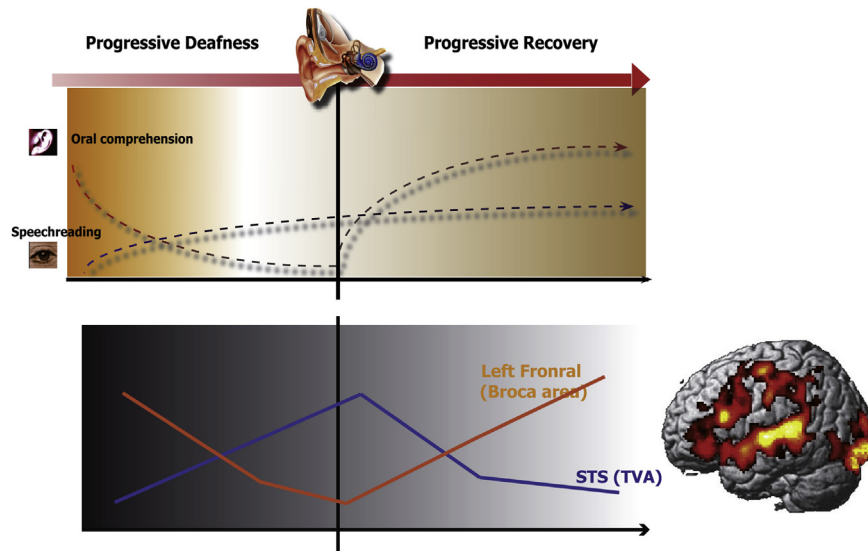
Thus, it appears that visual processing is closely related to the functional reorganization that occurs in the auditory cortex during deafness. This challenges the question whether there is a deleterious effect of visual speech processing on the capacity of deaf patients to recover auditory speech comprehension after cochlear implantation. In pre-lingual deaf patients, it has been established that the colonization of the auditory areas by visual functions proscribes a restoration of auditory speech processing (Lee et al., 2001). Further, in postlingual CI patients vision can be deleterious for non-speech (Champoux et al., 2009; Doucet et al., 2006) or during incongruent or ambiguous audiovisual conditions (Rouger et al., 2008). However, in post-lingually deaf CI patients we provided evidence against the deleterious role of visual activity. We showed that the activity in the occipital cortex involved in visual processing presents a crucial positive predictive capacity for auditory recovery in CI patients (Strelnikov et al., 2013). In this study, we correlated brain activity at the time of implantation with auditory speech comprehension scores at about 6 months post-implantation. We observed that visual activity was the most strongly correlated with auditory recuperation independently of the type of stimulation and even at rest. This is due to the crucial positive influence of the visual modality on the efficiency of auditory speech comprehension in CI patients (Rouger et al., 2007; Strelnikov et al., 2008) reflecting intramodal compensation mechanisms (see (Doucet et al., 2006). This study of the prognosis of CI outcomes based on brain activity also revealed an activity in superior temporal sulcus (STS), which was negatively correlated with speech comprehension scores later in time. In inexperienced CI patients (Rouger et al., 2012), speech reading induced high activity in this auditory area known to be involved in processing human voice stimuli (temporal voice-sensitive areas-TVA (Belin et al., 2000). Later, in experienced CI patients this activity level decreased approaching the level in controls (Rouger et al., 2012). Thus, this voice-specific area in STS is likely to be colonised by visual functions and the high level of this colonisation may interfere with auditory recuperation after implantation. On the contrary, activity level elicited in Broca's

area in inexperienced CI patients were abnormally low and increased in experienced CI patients being the highest in controls. In another study, Broca area was also activated as an effect of time post-implantation but only in CI listeners with postlingual hearing loss (Petersen et al., 2013).

Thus, a decrease of activity in the voice-sensitive areas in experienced CI patients is accompanied by the increase of speech processing in Broca area (Fig. 1). During deafness, the voice-specific temporal areas through cross-modal reorganization are reallocated to face processing as a support to speech-related visual strategy in deaf patients. After cochlear implantation, compensatory visual activity in these areas is gradually replaced by the normal voice-related activity. In parallel, there is a progressive restoration of the visuo-audio-motor speech processing loop with a crucial role of Broca area. These results are particularly in agreement with current theoretical approach attempting to link perception and action in an integrated framework (Basirat et al., 2012). Speech gestures are considered as motor coordination shaped by motor-to-sensory interactions suggesting that the perceptual and motor repertoires are developed in an interdependent way (Schwartz, 2010). This is already established in view of the strong consequences for the joint development of speech production and perception in deaf subjects (Menard et al., 2007).

As pointed previously, both behavioural (Arnold and Hill, 2001; Campbell, 2008; Reisberg et al., 1987) and brain imaging studies have demonstrated the benefits obtained from multisensory interaction including speech processing. Such interaction evolves progressively as long as the patients recover auditory functions. We have shown that cochlear implant users develop a strong visuo-auditory perceptive strategy for speech intelligibility (Rouger et al., 2007). This adaptive mechanism develops during the first three months post-implantation before being stabilized. Indeed, in a study comparing audiovisually presented words with separate auditory (A) and visual (V) presentations (Nishimura et al., 2000) found activations in the visual cortex in both short- and long-term uCI users. However, in the AV-V contrast there were significant activations in the left auditory and speech related cortex only in the long-term CI users. This demonstrates the changing role of cross-modal audiovisual integration parallel to auditory recuperation. At first, shortly after implantation, patients rely more on the visual strategies. With the development of auditory function, audiovisual integration is becoming stronger (Rouger et al., 2007) where visual information serves as feedback to reduce the ambiguity of the auditory information.

Using independent component analysis of PET data (Barone et al., 2013), we showed that experienced CI patients had greater activity in the left middle temporal cortex, known for audiovisual integration, compared with neo-users and controls. Patients at both time periods after implantation had a task-related component in the visual cortex. Importantly, the time course of temporal and visual activity in experienced patients was highly correlated. This coupling is crucial to adjust cross-modal plasticity, which is necessary for the recovery of speech comprehension in adult cochlear implanted deaf patients. We suggested the existence of synergetic neural facilitation mechanisms so that a better functional level of one modality leads to the better performance of the other. Such cooperation may be a reflection of the multisensory nature of speech communication. Furthermore, these results reinforce the crucial role of the audiovisual integration strategies that are strongly enhanced in CI users to compensate for the poor information delivered by the implant (Lee et al., 2005, 2007b). This complementary role of the visual channel is confirmed by the tendency for the implantees to activate the visual areas in the congruent audiovisual condition but not in the incongruent one (Song et al., 2014).



**Fig. 1.** Speech-related reorganisation of brain activity after CI in postlingually deaf patients. Schematic representation of the implication of visual and auditory processing of speech during deafness and after cochlear implantation. During deafness, voice-specific temporal areas in STS are colonized by visual modality (face processing) to support the speech-related visual strategy in deaf patients. After cochlear implantation, compensatory visual activity in these areas is gradually replaced by the normal voice-related activity. In parallel, there is a progressive restoration of the visuo-audio-motor speech processing loop with the corresponding activity increase in Broca area. The reorganisation of this network after deafness leads to the improvement in oral comprehension as illustrated in this scheme.

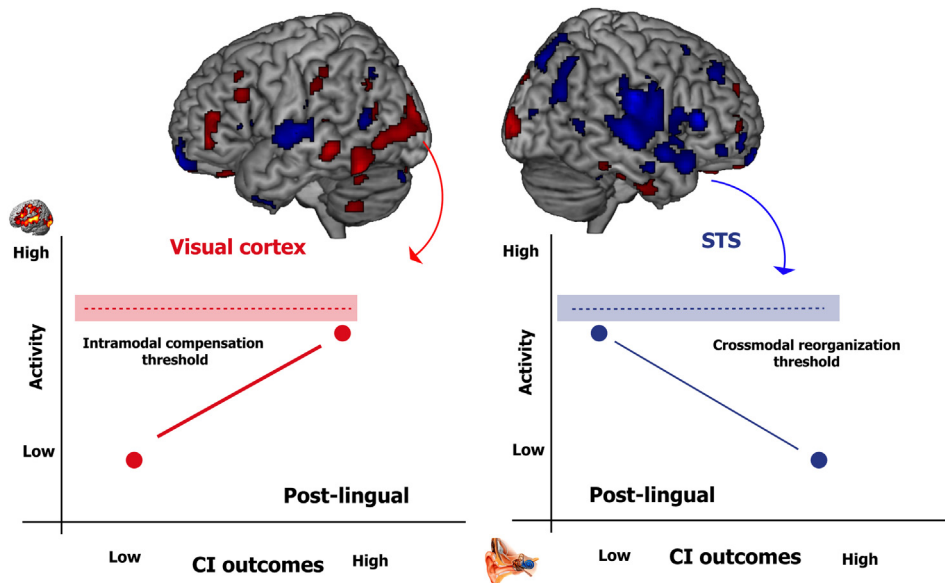
However, there is a crucial difference concerning the role of the visual cortex between post-lingually and pre-lingually deaf patients (Lee et al., 2005, 2007b). In pre-lingually deaf patients, poor CI performers present a higher resting state activity in the visual occipital cortex and fusiform gyrus (Lee et al., 2005). Further, using a liberal statistical threshold, the same visual areas were negatively correlated to CI outcomes (Lee et al., 2007b). These results have been interpreted as the consequence of intra- and cross-modal reorganizations that occur during deafness. In pre-lingually deaf patients, the acquisition of speech-reading skills or sign language as sensory substitution strategies for speech comprehension is linked to functional reorganization (Bavelier and Neville, 2002) expressed as activations of the auditory areas by visual linguistic information (Nishimura et al., 1999; Petitto et al., 2000). Thus, long-term colonization of the auditory areas by visual speech processing in pre-lingually deaf CI users interferes with auditory treatment (Lee et al., 2001).

A key element in the consideration of this issue is the role of the auditory STS (or STG where G stands for gyrus) region. In pre-lingually deaf CI users (Lee et al., 2007b), a high activity level in both the visual and STG/STS is associated with a low level of auditory recovery, leading to a positive correlation between the activity levels in these two regions. The high visual cortex activity in pre-lingually deaf CI users may be explained by intra-modal compensation within the visual system (Sandmann et al., 2012) and the high STG/STS activity by the cross-modal reorganization of the auditory system.

On the contrary, in post-lingually deaf adult CI patients, intra-modal compensation in the visual area and a weaker level of cross-modal reorganization of the auditory STG/STS are associated with a high CI outcome. In consequence, the activity levels in these two regions are inversely correlated (Fig. 2). We hypothesized that the order of magnitude of intra- and cross-modal plasticity may depend on the duration of deafness. It may act directly on the reversibility of the functional reorganization leading to a clear distinction between the CI outcomes of pre- and post-lingually deaf CI patients.

## 6. Processing of paralinguistic information in CI patients

While cochlear implantation allows most patients to understand speech, CI users usually experience difficulties in recognizing paralinguistic information due to degradation of the acoustic signal after acoustic-to-electric coding. Indeed, generally patients have difficulty in discriminating human voices from environmental sounds as well as some voice features such as gender of the talker (Cleary and Pisoni, 2002; Fu et al., 2004, 2005; Massida et al., 2011; Massida et al., 2013). Coding strategies developed for speech comprehension may penalize the processing of paralinguistic cues such as voice gender discrimination in CI users (Fu et al., 2004, 2005) but another source of this deficit in CI users could be the dysfunction of the auditory pathway, i.e. a suboptimal reorganization of cortical regions normally devoted to sound processing. Neuropsychological studies have revealed specific cortical regions mostly located in the temporal lobe where the lesion induces a specific impairment in voice recognition or phonagnosia (Hailstone et al., 2010; Neuner and Schweinberger, 2000; Van Lancker and Canter, 1982). Further, brain imaging studies have confirmed that areas along the upper bank of the middle and anterior parts of the superior temporal sulcus (STS), are involved in the processing of voice information (Belin et al., 2002, 2000). Only few studies have analysed the pattern of brain activity in response to voice in CI patients. Indeed, a recent brain imaging study reported a reduction in activation of the voice sensitive regions in experienced cochlear implanted subjects (Coez et al., 2008). Of importance, this absence in sensitivity of the temporal voice areas to human voice stimuli is observed in patients with low recovery of speech comprehension (Coez et al., 2008). During voice processing, a comparison of the binaural and the monaural stimulation condition in bilateral CI users revealed a tendency for the additional right temporal activation in the binaural condition, and during sound (voice + non-voice) processing a tendency for the activation of the right fronto-parietal cortical network implicated in attention (Coez et al., 2013). The fact that the pattern of brain activation in bilateral CI patients is closer to norm has been



**Fig. 2.** Brain activity and the outcome of CI in postlingually deaf patients. Representation at a liberal statistical threshold of the cortical areas, in which the activity levels at time of implantation are positively (red) or negatively (blue) correlated to the auditory speech comprehension (Strelnikov et al., 2013). This representation reveals the opposite implication of a ventral visual network and the STS region. The high CI outcome depends on two neural processes: the initial intra-modal compensation in the visual cortex (on the left) and a weak level of cross-modal reorganization of the auditory STS (on the right). In consequence, activity levels in these two regions measured shortly after implantation are inversely correlated. This scheme demonstrates the importance of proper interactions in the audiovisual neural network for the success of CI.

interpreted as a potential benefit in bilateral CI to provide enhanced spectral cues information that can be used to discriminate human voice from natural environmental sound (Marx et al., 2014). However, the lack of activation of the STS voice sensitive areas in unilateral CI patients could reflect crossmodal reorganization during deafness: in early CI deaf patients, there is an activation of the right STS during the visual speech reading task (Rouger et al., 2012). Such colonization of the voice sensitive area by visual function could be deleterious to the original function recovery in the auditory STS. This is in agreement with the fact that the right STS is weakly activated in CI patients presenting a low level of speech comprehension recovery (Coez et al., 2008) as these patient rely probably more on visual information to understand spoken language.

As previously mentioned, perception and enjoyment of music still represent a strong deficit in CI users (Cooper et al., 2008; Cullington and Zeng, 2011); music processing, which is important for quality of life of the patients, should also be ameliorated. Instrumental passages are hardly perceived and recognized because melody and timbre representation rely on complex and diverse acoustical cues, which are inefficiently transmitted through the implant (Gfeller et al., 2002). When compared with controls during listening to music and rhythm, CI subjects had a tendency of greater temporal cortex activation for all conditions and there were no foci of temporal cortex that showed greater activity in control subjects under any condition (Limb et al., 2010). This shows that CI users treat musical signals differently from controls but more brain imaging studies are needed to understand what compensatory strategies are used by the brain to decipher the distorted by the implant acoustic signal in what concerns music and paralinguistic information. Another important perspective would be to understand neural mechanisms that link music and speech processing given the evidence that musical training can promote the restoration of speech perception in CI users (Petersen et al., 2009).

## 7. Conclusions and perspectives

Brain mechanisms of auditory recuperation in CI patients involve a functional reorganisation of the auditory and linguistic brain networks and present a different pattern of brain activity both while acoustic stimulation and at rest. Early after implantation, these networks include brain areas involved in the integrative processing of the auditory, visual and linguistic information. Importantly, the existing PET studies of speech perception in CI patients used only separate words and syllables as stimulation. However, continuous speech is ecologically more used and it involves a lot of contextual and predictive cues, absent in separate words and syllables, as well as the particular syntactic and prosodic properties (Strelnikov, 2008). Thus, studies of continuous speech processing in CI present a further perspective. Moving towards ecological communicative situations, PET studies on social interactions and the usage of environmental information for speech comprehension also present a perspective.

Lastly, using various protocols, recent studies have established a correlation between a level of brain activity close to the time of implantation and the auditory performance several weeks/month later (Lazard et al., 2012; Lee et al., 2007b; Strelnikov et al., 2013). Such results have an important clinical significance. In postlingually deaf adult CI users, high progress of speech recovery is observed during the first year after cochlear implantation, but there is a large range of variability in the level of CI outcomes and in the temporal evolution of recovery (Rouger et al., 2007). Once the obvious pathological grounds are discarded, the causes of such variability are multiple, including severity, duration, and the age of onset of the hearing loss (Blamey et al., 2013; Lazard et al., 2012). In consequence, brain imaging performed at the time of activation of the cochlear implant offers the possibility of obtaining a predictive diagnosis with simple resting-state conditions that can be easily standardized across clinical centers. Though PET brain imaging presents a small radioactive burden, it offers numerous advantages

compared to fMRI, among which the possibility to obtain an absolute value of the resting state activity level in CI patients. Still, a multi-center clinical trial should first be performed in order to establish the regression functions that would precisely estimate the inter-individual and between-center variability. Once these functions established, they can be used to evaluate the potential of recovery of any single patient. Based on that prediction, a specific rehabilitation program can be adapted to the patient in order to fasten or optimize his speech comprehension recovery.

## Acknowledgements

This work was supported by the ANR Plasmody (ANR-11-BSHS2-0008 to BP and OD), The DRICI Toulouse (Direction de la Recherche Clinique et de l'Innovation to KS), the region Midi-Pyrénées (RTT N° 10006537 to KS and BP) the Fondation pour la Recherche Médicale (to S.L.), and the recurrent funding of the CNRS (to OD and BP).

## References

- Aggarwal, R., Green, K.M., 2012. Cochlear implants and positron emission tomography. *J. laryngol. otol.* 126, 1200–1203.
- Arnold, P., Hill, F., 2001. Bisenory augmentation: a speechreading advantage when speech is clearly audible and intact. *Br. J. Psychol.* 92 (Part 2), 339–355.
- Barone, P., Deguine, O., 2011. Multisensory processing in cochlear implant listeners. In: Zeng, F.G., Fay, R., Popper, A. (Eds.), *Springer Handbook of Auditory Research. Auditory Prostheses: Cochlear Implants and Beyond*. Springer-Verlag, New-York, pp. 365–382.
- Barone, P., Strelnikov, K., Déguine, O., 2013. Role of audiovisual plasticity in speech recovery after adult cochlear implantation. In: Ouni, S., Berthomier, F., Jesse, A. (Eds.), *The 12th International Conference on Auditory-visual Speech Processing*. Anney, France, pp. 99–104.
- Basirat, A., Schwartz, J.L., Sato, M., 2012. Perceptuo-motor interactions in the perceptual organization of speech: evidence from the verbal transformation effect. *Philos. Trans. R. Soc. Lond. B Biol. Sci.* 367, 965–976.
- Bavelier, D., Neville, H.J., 2002. Cross-modal plasticity: where and how? *Nat. Rev.* 3, 443–452.
- Belin, P., Zatorre, R.J., Ahad, P., 2002. Human temporal-lobe response to vocal sounds. *Brain Res. Cogn. Brain Res.* 13, 17–26.
- Belin, P., Zatorre, R.J., Lafaille, P., Ahad, P., Pike, B., 2000. Voice-selective areas in human auditory cortex. *Nature* 403, 309–312.
- Bennett, C.M., Wolford, G.L., Miller, M.B., 2009. The principled control of false positives in neuroimaging. *Soc. Cogn. Affect Neurosci.* 4, 417–422.
- Benoit, C., Mohamadi, T., Kandel, S., 1994. Effects of phonetic context on audio-visual intelligibility of French. *J. Speech Hear. Res.* 37, 1195–1203.
- Bernstein, L.E., Demorest, M.E., Tucker, P.E., 2000. Speech perception without hearing. *Percept. Psychophys.* 62, 233–252.
- Bernstein, L.E., Auer, E.T., Tucker, P.E., 2001. Enhanced speechreading in deaf adults: can short-term training/practice close the gap for hearing adults? *J. Speech, Lang. Hear. Res.* 44, 5–18.
- Blamey, P., Artieres, F., Baskent, D., Bergeron, F., Beynon, A., Burke, E., Dillier, N., Dowell, R., Frayse, B., Gallego, S., Govaerts, P.J., Green, K., Huber, A.M., Kleine-Punte, A., Maat, B., Marx, M., Mawman, D., Mosnier, I., O'Connor, A.F., O'Leary, S., Rousset, A., Schauwers, K., Skarzynski, H., Skarzynski, P.H., Sterkers, O., Terranti, A., Truy, E., Van de Heyning, P., Venail, F., Vincent, C., Lazard, D.S., 2013. Factors affecting auditory performance of postlinguistically deaf adults using cochlear implants: an update with 2251 patients. *Audiol. Neuro Otol.* 18, 36–47.
- Campbell, R., 2008. The processing of audio-visual speech: empirical and neural bases. *Philos. Trans. R. Soc. Lond.* 363, 1001–1010.
- Champoux, F., Lepore, F., Gagne, J.P., Theoret, H., 2009. Visual stimuli can impair auditory processing in cochlear implant users. *Neuropsychologia* 47, 17–22.
- Cleary, M., Pisoni, D.B., 2002. Talker discrimination by prelingually deaf children with cochlear implants: preliminary results. *Ann. otol. rhinol. laryngol.* 189, 113–118.
- Coez, A., Zilbovicius, M., Ferrary, E., Bouccara, D., Mosnier, I., Ambert-Dahan, E., Bizaguet, E., Syrota, A., Samson, Y., Sterkers, O., 2008. Cochlear implant benefits in deafness rehabilitation: PET study of temporal voice activations. *J. Nucl. Med.* 49, 60–67.
- Coez, A., Zilbovicius, M., Ferrary, E., Bouccara, D., Mosnier, I., Ambert-Dahan, E., Bizaguet, E., Martinot, J.L., Samson, Y., Sterkers, O., 2013. Brain voice processing with bilateral cochlear implants: a positron emission tomography study. *Eur. Arch. Otorhinolaryngol.* (in press).
- Conte, W.L., Kamishina, H., Corwin, J.V., Reep, R.L., 2008. Topography in the projections of lateral posterior thalamus with cingulate and medial agranular cortex in relation to circuitry for directed attention and neglect. *Brain Res.* 1240, 87–95.
- Cooper, W.B., Tobey, E., Loizou, P.C., 2008. Music perception by cochlear implant and normal hearing listeners as measured by the montreal battery for evaluation of Amusia. *Ear Hear.* 29, 618–626.
- Crane, B.T., Gottschalk, B., Kraut, M., Aygun, N., Niparko, J.K., 2010. Magnetic resonance imaging at 1.5 T after cochlear implantation. *Otol. Neurotol.* 31, 1215–1220.
- Cullington, H.E., Zeng, F.G., 2011. Comparison of bimodal and bilateral cochlear implant users on speech recognition with competing talker, music perception, affective prosody discrimination, and talker identification. *Ear Hear.* 32, 16–30.
- Debener, S., Hine, J., Bleeck, S., Eyles, J., 2008. Source localization of auditory evoked potentials after cochlear implantation. *Psychophysiology* 45, 20–24.
- Deggouj, N., Gersdorff, M., Garin, P., Castelein, S., Gerard, J.M., 2007. Today's indications for cochlear implantation. *B-Ent* 3, 9–14.
- Deggouj, N., Devolder, A., Catalan, M., Melin, J., Michel, C., Gersdorff, M., Veraart, C., 1995. Positron emission tomography in deaf patients at rest. *Adv. oto-rhinolaryngol.* 50, 31–37.
- Doucet, M.E., Bergeron, F., Lassonde, M., Ferron, P., Lepore, F., 2006. Cross-modal reorganization and speech perception in cochlear implant users. *Brain* 129, 3376–3383.
- Dunn, C.C., Tyler, R.S., Oakley, S., Gantz, B.J., Noble, W., 2008. Comparison of speech recognition and localization performance in bilateral and unilateral cochlear implant users matched on duration of deafness and age at implantation. *Ear Hear.* 29, 352–359.
- Fiser, J., Chiu, C., Weliky, M., 2004. Small modulation of ongoing cortical dynamics by sensory input during natural vision. *Nature* 431, 573–578.
- Friston, K.J., 2003. Introduction: experimental design and statistical parametric mapping. In: Frackowiak, R.S.J., Friston, K.J., Frith, C., Dolan, R., Price, C.J., Zeki, S., Ashburner, J., Penny, W.D. (Eds.), *Human Brain Function*. Academic Press.
- Fu, Q.J., Chinchilla, S., Galvin, J.J., 2004. The role of spectral and temporal cues in voice gender discrimination by normal-hearing listeners and cochlear implant users. *J. Assoc. Res. Otolaryngol.* 5, 253–260.
- Fu, Q.J., Chinchilla, S., Nogaki, G., Galvin 3rd, J.J., 2005. Voice gender identification by cochlear implant users: the role of spectral and temporal resolution. *J. Acoust. Soc. Am.* 118, 1711–1718.
- Fujiki, N., Naito, Y., Hirano, S., Kojima, H., Shiomi, Y., Nishizawa, S., Honjo, I., 2000. Brain activities of prelingually and postlingually deafened children using cochlear implants. *Ann. otol. rhinol. laryngol.* 185, 12–14.
- Gfeller, K., Witt, S., Woodworth, G., Mehr, M.A., Knutson, J., 2002. Effects of frequency, instrumental family, and cochlear implant type on timbre recognition and appraisal. *Ann. otol. rhinol. laryngol.* 111, 349–356.
- Giove, F., Mangia, S., Bianciardi, M., Garreffa, G., Di Salle, F., Morrone, R., Maraviglia, B., 2003. The physiology and metabolism of neuronal activation: in vivo studies by NMR and other methods. *Magn. Reson. Imaging* 21, 1283–1293.
- Giraud, A.L., Lee, H.J., 2007. Predicting cochlear implant outcome from brain organisation in the deaf. *Restor. Neurol. Neurosci.* 25, 381–390.
- Giraud, A.L., Price, C.J., Graham, J.M., Frackowiak, R.S., 2001a. Functional plasticity of language-related brain areas after cochlear implantation. *Brain* 124, 1307–1316.
- Giraud, A.L., Price, C.J., Graham, J.M., Truy, E., Frackowiak, R.S., 2001b. Cross-modal plasticity underpins language recovery after cochlear implantation. *Neuron* 30, 657–663.
- Giraud, A.L., Truy, E., Frackowiak, R.S., Gregoire, M.C., Pujol, J.F., Collet, L., 2000. Differential recruitment of the speech processing system in healthy subjects and rehabilitated cochlear implant patients. *Brain* 123, 1391–1402.
- Grant, K.W., Braid, L.D., 1991. Evaluating the articulation index for auditory-visual input. *J. Acoust. Soc. Am.* 89, 2952–2960.
- Green, K.M., Julyan, P.J., Hastings, D.L., Ramsden, R.T., 2005. Auditory cortical activation and speech perception in cochlear implant users: effects of implant experience and duration of deafness. *Ear Hear.* 205, 184–192.
- Green, K.M., Julyan, P.J., Hastings, D.L., Ramsden, R.T., 2008. Auditory cortical activation and speech perception in cochlear implant users. *J. laryngol. otol.* 122, 238–245.
- Gusnard, D.A., Raichle, M.E., 2001. Searching for a baseline: functional imaging and the resting human brain. *Nat. Rev. Neurosci.* 2, 685–694.
- Hailstone, J.C., Crutch, S.J., Vestergaard, M.D., Patterson, R.D., Warren, J.D., 2010. Progressive associative phonagnosia: a neuropsychological analysis. *Neuropsychologia* 48, 1104–1114.
- Hans, J., Veuillet, E., Adjout, K., Besle, J., Collet, L., Thai-Van, H., 2009. The effect of long-term unilateral deafness on the activation pattern in the auditory cortices of French-native speakers: influence of deafness side. *BMC Neurosci.* 10, 23.
- Ito, J., Sakakibara, J., Iwasaki, Y., Yonekura, Y., 1993. Positron emission tomography of auditory sensation in deaf patients and patients with cochlear implants. *Ann. otol. rhinol. laryngol.* 102, 797–801.
- Ito, K., Momose, T., Oku, S., Ishimoto, S., Yamasoba, T., Sugawara, M., Kaga, K., 2004. Cortical activation shortly after cochlear implantation. *Audiol. neuro-otol.* 9, 282–293.
- Kang, E., Lee, D.S., Kang, H., Lee, J.S., Oh, S.H., Lee, M.C., Kim, C.S., 2004. Neural changes associated with speech learning in deaf children following cochlear implantation. *NeuroImage* 22, 1173–1181.
- Kenet, T., Bibitchkov, D., Tsodyks, M., Grinvald, A., Arieli, A., 2003. Spontaneously emerging cortical representations of visual attributes. *Nature* 425, 954–956.
- Lazard, D.S., Vincent, C., Venail, F., Van de Heyning, P., Truy, E., Sterkers, O., Skarzynski, P.H., Skarzynski, H., Schauwers, K., O'Leary, S., Mawman, D., Maat, B., Kleine-Punte, A., Huber, A.M., Green, K., Govaerts, P.J., Frayse, B., Dowell, R., Dillier, N., Burke, E., Beynon, A., Bergeron, F., Baskent, D., Artieres, F., Blamey, P.J.,

2012. Pre-, per- and postoperative factors affecting performance of post-linguistically deaf adults using cochlear implants: a new conceptual model over time. *PLoS One* 7, e48739.
- Lee, D.S., Lee, J.S., Oh, S.H., Kim, S.K., Kim, J.W., Chung, J.K., Lee, M.C., Kim, C.S., 2001. Cross-modal plasticity and cochlear implants. *Nature* 409, 149–150.
- Lee, H.J., Truy, E., Mamou, G., Sappey-Marinié, D., Giraud, A.L., 2007a. Visual speech circuits in profound acquired deafness: a possible role for latent multimodal connectivity. *Brain* 130, 2929–2941.
- Lee, H.J., Kang, E., Oh, S.H., Kang, H., Lee, D.S., Lee, M.C., Kim, C.S., 2005. Preoperative differences of cerebral metabolism relate to the outcome of cochlear implants in congenitally deaf children. *Hear Res.* 203, 2–9.
- Lee, H.J., Giraud, A.L., Kang, E., Oh, S.H., Kang, H., Kim, C.S., Lee, D.S., 2007b. Cortical activity at rest predicts cochlear implantation outcome. *Cereb. Cortex* 17, 909–917.
- Limb, C.J., Molloy, A.T., Jiradejvong, P., Braun, A.R., 2010. Auditory cortical activity during cochlear implant-mediated perception of spoken language, melody, and rhythm. *J. Assoc. Res. Otolaryngol.* 11, 133–143.
- MacLeod, A., Summerfield, Q., 1987. Quantifying the contribution of vision to speech perception in noise. *Br. J. Audiol.* 21, 131–141.
- MacSweeney, M., Calvert, G.A., Campbell, R., McGuire, P.K., David, A.S., Williams, S.C., Woll, B., Brammer, M.J., 2002. Speechreading circuits in people born deaf. *Neuropsychologia* 40, 801–807.
- Marx, M., James, C., Foxton, J., Capber, A., Fraysse, B., Barone, P., Deguine, O., 2014. Impact of residual hearing on speech prosody perception in cochlear implant users. *Ear Hear.* (in press).
- Massida, Z., Belin, P., James, C., Rouger, J., Fraysse, B., Barone, P., Deguine, O., 2011. Voice discrimination in cochlear-implanted deaf subjects. *Hear. Res.* 275, 120–129.
- Massida, Z., Marx, M., Belin, P., James, C., Fraysse, B., Barone, P., Deguine, O., 2013. Gender categorization in cochlear implant users. *J. Speech Lang. Hear. Res.* 56, 1389–1401.
- Mazoyer, B., Zago, L., Mellet, E., Bricogne, S., Etard, O., Houde, O., Crivello, F., Joliot, M., Petit, L., Tzourio-Mazoyer, N., 2001. Cortical networks for working memory and executive functions sustain the conscious resting state in man. *Brain Res. Bull.* 54, 287–298.
- Menard, L., Polak, M., Denny, M., Burton, E., Lane, H., Matthies, M.L., Marrone, N., Perkell, J.S., Tiede, M., Vick, J., 2007. Interactions of speaking condition and auditory feedback on vowel production in postlingually deaf adults with cochlear implants. *J. Acoust. Soc. Am.* 121, 3790–3801.
- Moller, A.R., 2006. History of cochlear implants and auditory brainstem implants. *Adv. oto-rhino-laryngol.* 64, 1–10.
- Mosnier, I., Sterkers, O., Bebear, J.P., Godey, B., Robier, A., Deguine, O., Fraysse, B., Bordure, P., Mondain, M., Bouccara, D., Bozorg-Grayeli, A., Borel, S., Ambert-Dahan, E., Ferrary, E., 2009. Speech performance and sound localization in a complex noisy environment in bilaterally implanted adult patients. *Audiol. Neurootol.* 14, 106–114.
- Naito, Y., Tateya, I., Fujiki, N., Hirano, S., Ishizu, K., Nagahama, Y., Fukuyama, H., Kojima, H., 2000. Increased cortical activation during hearing of speech in cochlear implant users. *Hear. Res.* 143, 139–146.
- Naito, Y., Okazawa, H., Honjo, I., Hirano, S., Takahashi, H., Shiomi, Y., Hoji, W., Kawano, M., Ishizu, K., Yonekura, Y., 1995. Cortical activation with sound stimulation in cochlear implant users demonstrated by positron emission tomography. *Cogn. Brain Res.* 2, 207–214.
- Neuman, A.C., Haravon, A., Sisljan, N., Waltzman, S.B., 2007. Sound-direction identification with bilateral cochlear implants. *Ear Hear* 28, 73–82.
- Neuner, F., Schweinberger, S.R., 2000. Neuropsychological impairments in the recognition of faces, voices, and personal names. *Brain Cogn.* 44, 342–366.
- Nishimura, H., Hashikawa, K., Doi, K., Iwaki, T., Watanabe, Y., Kusuoka, H., Nishimura, T., Kubo, T., 1999. Sign language 'heard' in the auditory cortex. *Nature* 397, 116.
- Nishimura, H., Doi, K., Iwaki, T., Hashikawa, K., Oku, N., Teratani, T., Hasegawa, T., Watanabe, A., Nishimura, T., Kubo, T., 2000. Neural plasticity detected in short- and long-term cochlear implant users using PET. *Neuroreport* 11, 811–815.
- Okazawa, H., Naito, Y., Yonekura, Y., Sadato, N., Hirano, S., Nishizawa, S., Magata, Y., Ishizu, K., Tamaki, N., Honjo, I., Konishi, J., 1996. Cochlear implant efficiency in pre- and postlingually deaf subjects. A study with H2(15)O and PET. *Brain* 119 (Pt 4), 1297–1306.
- Peng, S.C., Lu, N., Chatterjee, M., 2009. Effects of cooperating and conflicting cues on speech intonation recognition by cochlear implant users and normal hearing listeners. *Audiol. neuro-otol.* 14, 327–337.
- Petersen, B., Mortensen, M.V., Gjedde, A., Vuust, P., 2009. Reestablishing speech understanding through musical ear training after cochlear implantation: a study of the potential cortical plasticity in the brain. *Ann. N. Y. Acad. Sci.* 1169, 437–440.
- Petersen, B., Gjedde, A., Wallentin, M., Vuust, P., 2013. Cortical plasticity after cochlear implantation. *Neural Plast.* 2013, 318521.
- Petitto, L.A., Zatorre, R.J., Gauna, K., Nikelski, E.J., Dostie, D., Evans, A.C., 2000. Speech-like cerebral activity in profoundly deaf people processing signed languages: implications for the neural basis of human language. *Proc. Natl. Acad. Sci. U. S. A.* 97, 13961–13966.
- Pollonini, L., Olds, C., Abaya, H., Bortfeld, H., Beauchamp, M.S., Oghalai, J.S., 2014. Auditory cortex activation to natural speech and simulated cochlear implant speech measured with functional near-infrared spectroscopy. *Hear. Res.* 309, 84–93.
- Raichle, M.E., Mintun, M.A., 2006. Brain work and brain imaging. *Annu. Rev. Neurosci.* 29, 449–476.
- Raichle, M.E., Snyder, A.Z., 2007. A default mode of brain function: a brief history of an evolving idea. *Neuroimage* 37, 1083–1090 discussion 1097–9.
- Reisberg, D., McLean, J., Goldfield, A., 1987. Easy to hear but hard to understand. In: Dodd, B., Campbell, R. (Eds.), *Hearing by Eye: the Psychology of Lipreading*. Erlbaum, Hillsdale, NJ, pp. 97–114.
- Ricketts, T.A., Grantham, D.W., Ashmead, D.H., Haynes, D.S., Labadie, R.F., 2006. Speech recognition for unilateral and bilateral cochlear implant modes in the presence of uncorrelated noise sources. *Ear Hear.* 27, 763–773.
- Ross, L.A., Saint-Amour, D., Leavitt, V.M., Javitt, D.C., Foxe, J.J., 2007. Do you see what I am saying? Exploring visual enhancement of speech comprehension in noisy environments. *Cereb. Cortex* 17, 1147–1153.
- Rouger, J., Fraysse, B., Deguine, O., Barone, P., 2008. McGurk effects in cochlear-implanted deaf subjects. *Brain Res.* 1188, 87–99.
- Rouger, J., Lagleyre, S., Fraysse, B., Deneuve, S., Deguine, O., Barone, P., 2007. Evidence that cochlear-implanted deaf patients are better multisensory integrators. *Proc. Natl. Acad. Sci. U. S. A.* 104, 7295–7300.
- Rouger, J., Lagleyre, S., Demonet, J.F., Fraysse, B., Deguine, O., Barone, P., 2012. Evolution of crossmodal reorganization of the voice area in cochlear-implanted deaf patients. *Hum. Brain Mapp.* 33, 1929–1940.
- Sandmann, P., Dillier, N., Eichele, T., Meyer, M., Kegel, A., Pascual-Marqui, R.D., Marcar, V.L., Jancke, L., Debener, S., 2012. Visual activation of auditory cortex reflects maladaptive plasticity in cochlear implant users. *Brain* 135, 555–568.
- Schwartz, J.L., 2010. A reanalysis of McGurk data suggests that audiovisual fusion in speech perception is subject-dependent. *J. Acoust. Soc. Am.* 127, 1584–1594.
- Sevy, A.B., Bortfeld, H., Huppert, T.J., Beauchamp, M.S., Tonini, R.E., Oghalai, J.S., 2010. Neuroimaging with near-infrared spectroscopy demonstrates speech-evoked activity in the auditory cortex of deaf children following cochlear implantation. *Hear. Res.* 270, 39–47.
- Song, J.J., Lee, H.J., Kang, H., Lee, D.S., Chang, S.O., Oh, S.H., 2014. Effects of congruent and incongruent visual cues on speech perception and brain activity in cochlear implant users. *Brain Struct. Funct.* (in press).
- Strelnikov, K., 2007. Can mismatch negativity be linked to synaptic processes? A glutamatergic approach to deviance detection. *Brain Cogn.* 244–251.
- Strelnikov, K., 2008. Activation-verification in continuous speech processing. Interaction of cognitive strategies as a possible theoretical approach. *J. Neurolinguistics* 21, 1–17.
- Strelnikov, K., Rouger, J., Lagleyre, S., Fraysse, B., Deguine, O., Barone, P., 2008. Improvement in speech-reading ability by auditory training: evidence from gender differences in normally hearing, deaf and cochlear implanted subjects. *Neuropsychologia* 47, 972–979.
- Strelnikov, K., Rouger, J., Lagleyre, S., Fraysse, B., Deguine, O., Barone, P., 2009. Improvement in speech-reading ability by auditory training: evidence from gender differences in normally hearing, deaf and cochlear implanted subjects. *Neuropsychologia* 47, 972–979.
- Strelnikov, K., Rouger, J., Demonet, J.F., Lagleyre, S., Fraysse, B., Deguine, O., Barone, P., 2010. Does brain activity at rest reflect adaptive strategies? Evidence from speech processing after cochlear implantation. *Cereb. Cortex* 20, 1217–1222.
- Strelnikov, K., Rouger, J., Demonet, J.-F., Lagleyre, S., Fraysse, B., Deguine, O., B. P., 2013. Visual activity predicts auditory recovery from deafness after adult cochlear implantation. *Brain* 136, 3682–3695.
- Strelnikov, K., Rouger, J., Eter, E., Lagleyre, S., Fraysse, B., Demonet, J.F., Barone, P., Deguine, O., 2011. Binaural stimulation through cochlear implants in postlingual deafness: a positron emission tomographic study of word recognition. *Otol. Neurotol.* 32, 1210–1217.
- Sumbly, W.H., Pollack, I., 1954. Visual contribution to speech intelligibility in noise. *J. Acoust. Soc. Am.* 26, 212–215.
- Summerfield, Q., 1979. Use of visual information for phonetic perception. *Phonetica* 36, 314–331.
- Tyler, R.S., Dunn, C.C., Witt, S.A., Noble, W.G., 2007. Speech perception and localization with adults with bilateral sequential cochlear implants. *Ear Hear* 28, 865–905.
- Tyler, R.S., Parkinson, A.J., Woodworth, G.G., Lowder, M.W., Gantz, B.J., 1997. Performance over time of adult patients using the Ineraid or Nucleus cochlear implant. *J. Acoust. Soc. Am.* 102, 508–522.
- UKCISG, 2004. Criteria of candidacy for unilateral cochlear implantation in post-lingually deafened adults I: theory and measures of effectiveness. *Ear Hear.* 25, 310–335.
- Van Lancker, D.R., Canter, G.J., 1982. Impairment of voice and face recognition in patients with hemispheric damage. *Brain Cogn.* 1, 185–195.
- Veraart, C., De Volder, A.G., Wanet-Defalque, M.C., Bol, A., Michel, C., Goffinet, A.M., 1990. Glucose utilization in human visual cortex is abnormally elevated in blindness of early onset but decreased in blindness of late onset. *Brain Res.* 510, 115–121.
- Wanet-Defalque, M.C., Veraart, C., De Volder, A., Metz, R., Michel, C., Dooms, G., Goffinet, A., 1988. High metabolic activity in the visual cortex of early blind human subjects. *Brain Res.* 446, 369–373.
- Wong, D., Miyamoto, R.T., Pisoni, D.B., Sehgal, M., Hutchins, G.D., 1999. PET imaging of cochlear-implant and normal-hearing subjects listening to speech and nonspeech. *Hear. Res.* 132, 34–42.